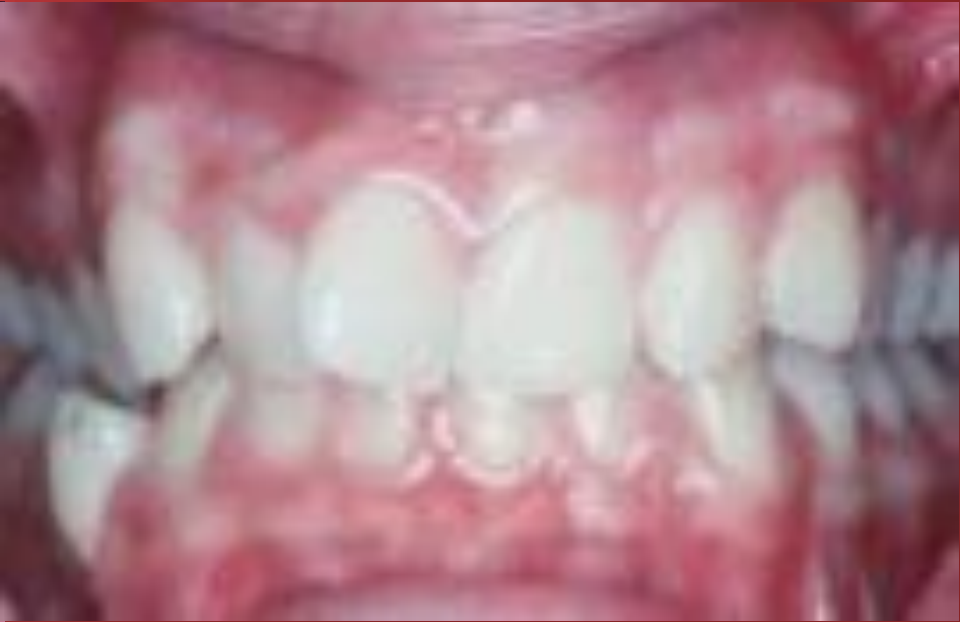
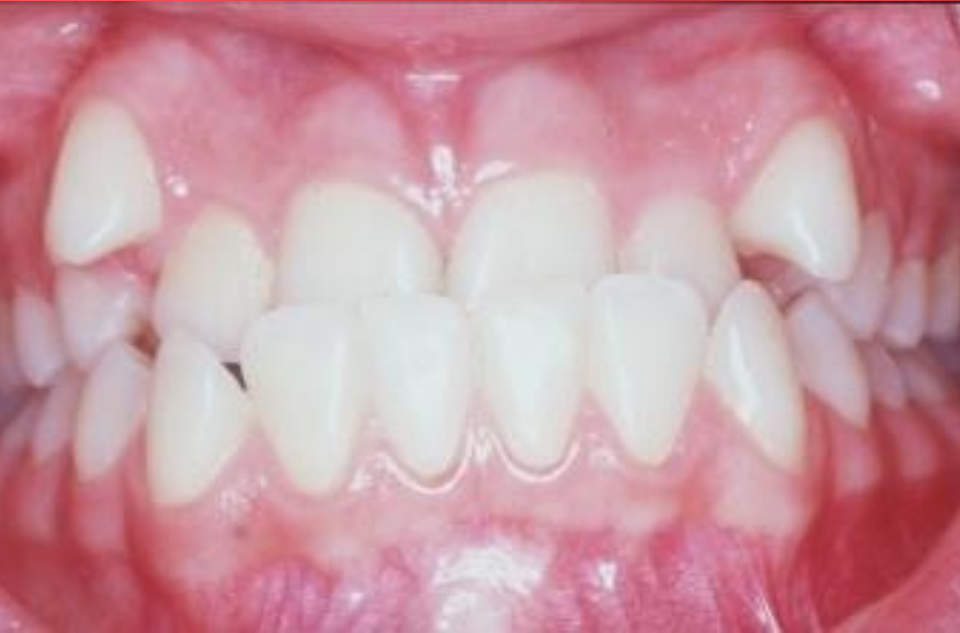
**PREVENTION
OF
OCCLUSAL
ABNORMALITIES**

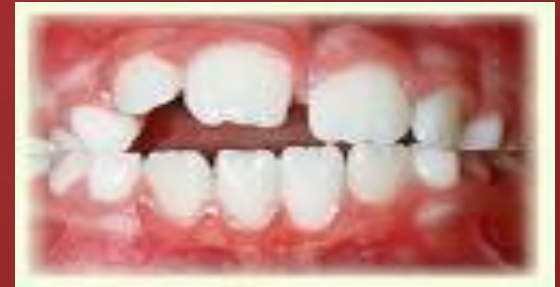Maintaining the individual in physiologic activity of teeth, soft tissue and facial and masticatory function is the aim of preventive dentistry

general practitioner should recognize early (at 5y.) deviations from normal dento-facial development of his young patients.

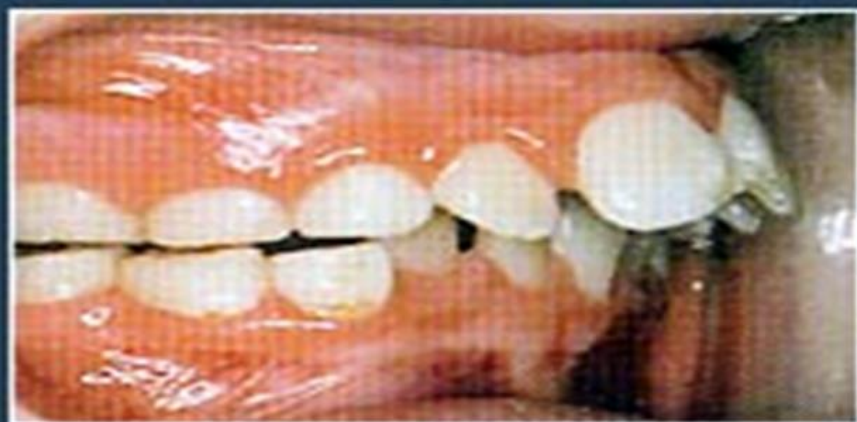The size, shape and quality of the teeth and jaws must be taken into account.



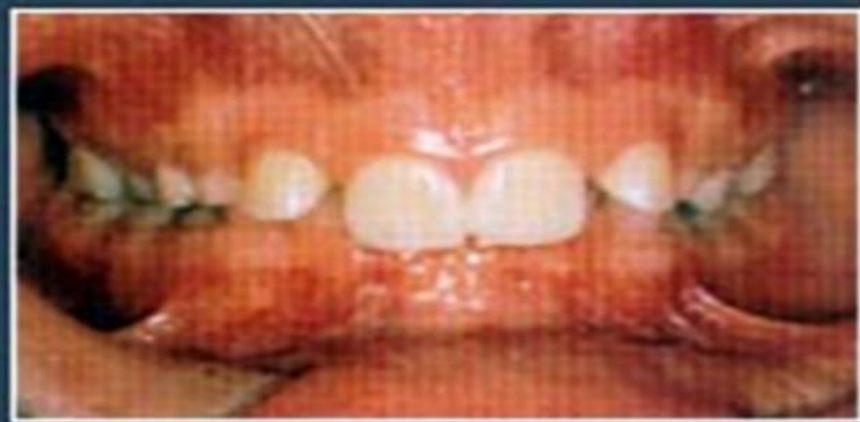Regular examinations of the child, careful recording of possibly harmful habits such as thumb and finger sucking, lip biting habits, tongue thrusting, incorrect swallowing patterns etc.



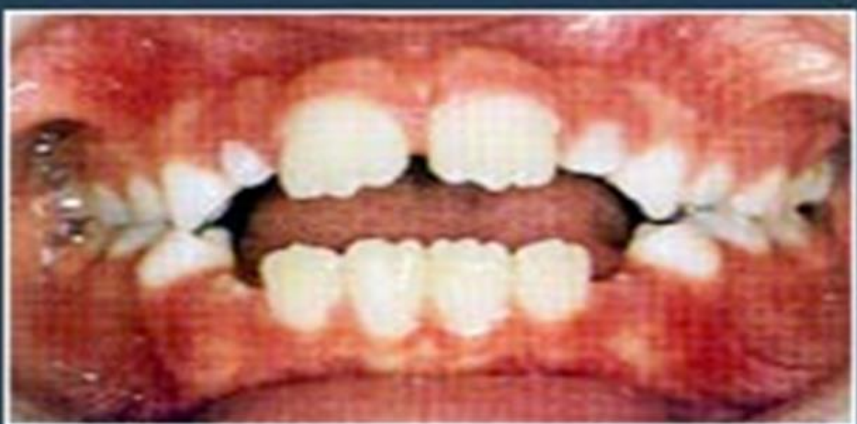Some of the deformities (such as anterior open bite associated with thumb and finger sucking) may correct themselves if the child stops the habit early, and therefore the dentist must be aware of the timing for interception.



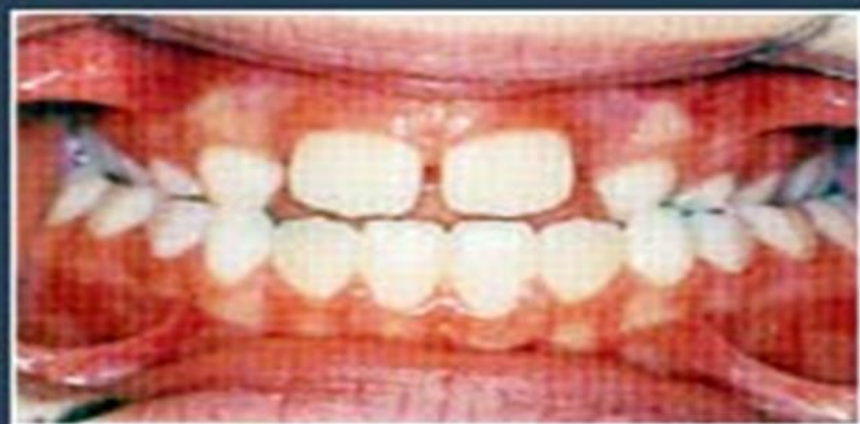Protrusion



Deep Overbite



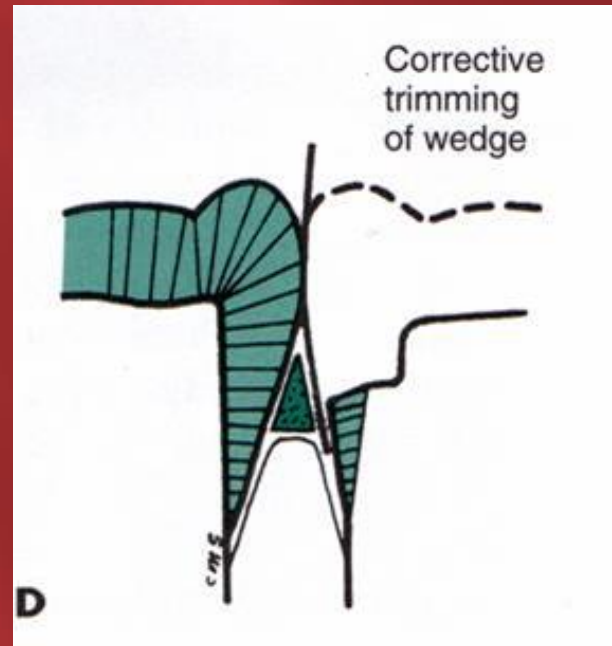
Openbite

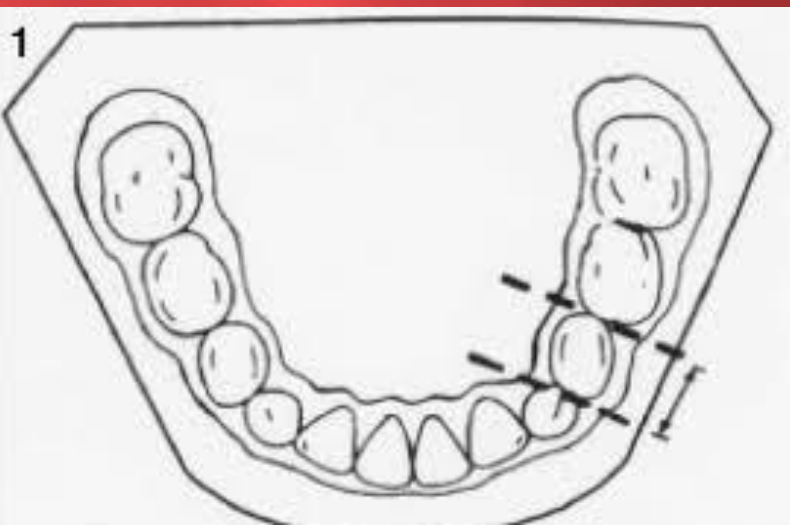
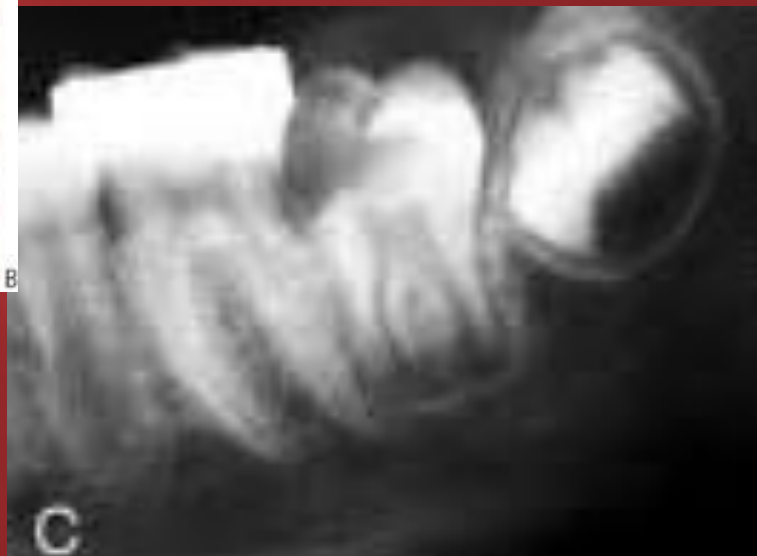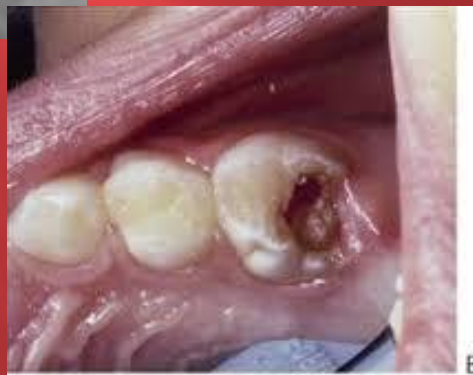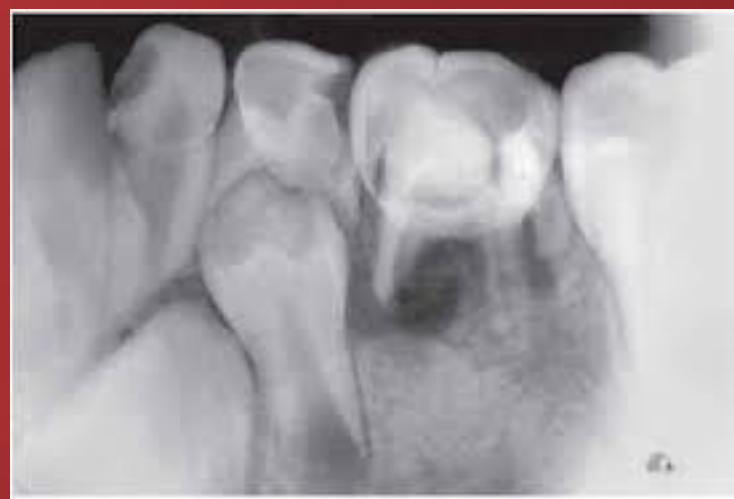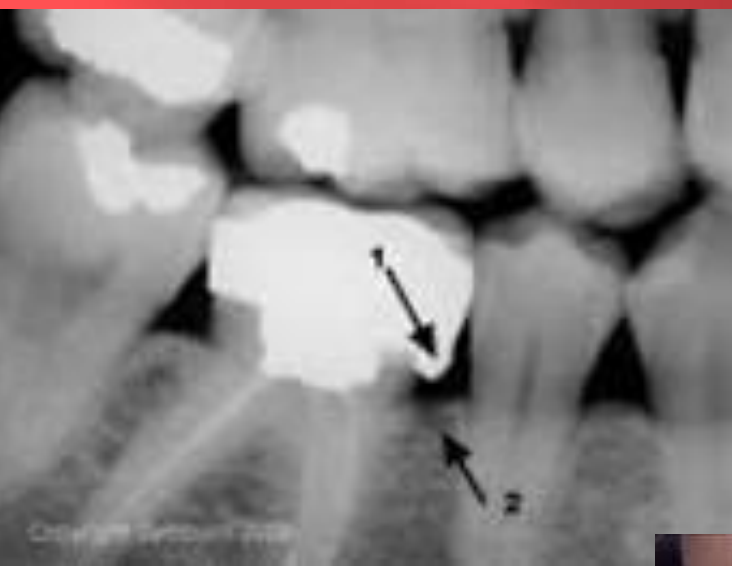


Crossbite

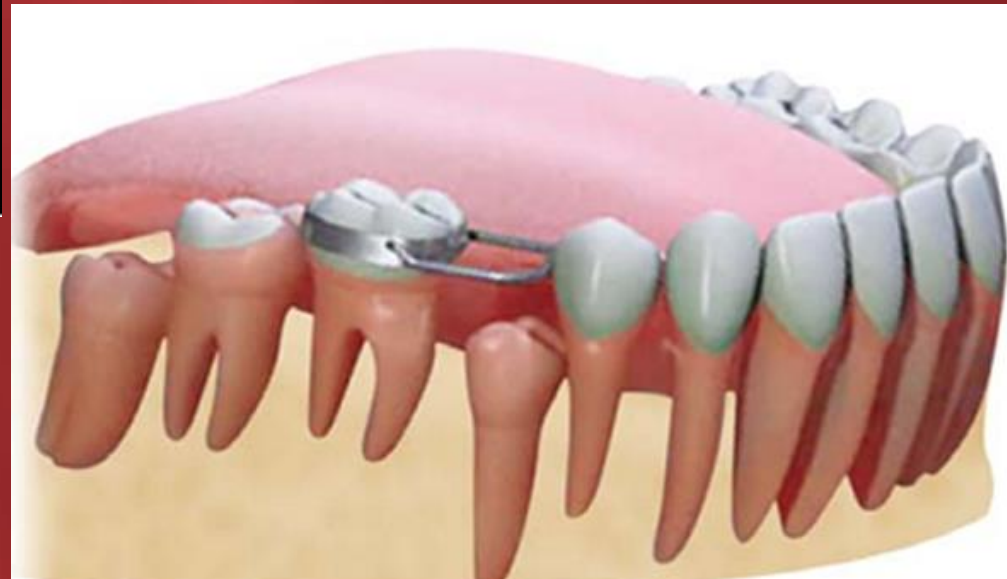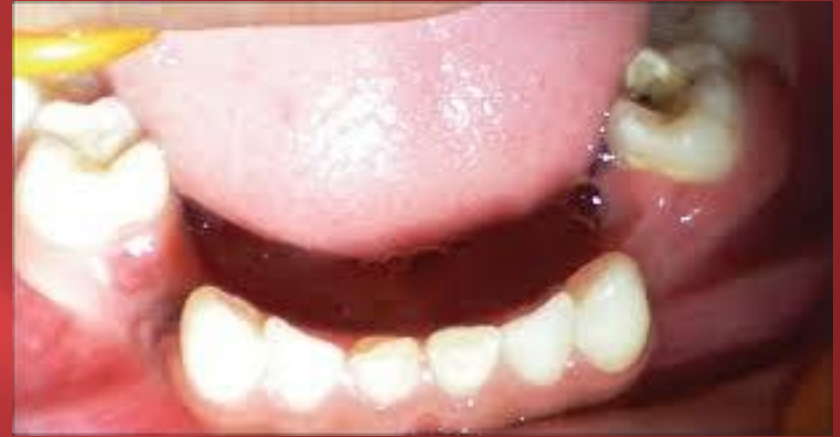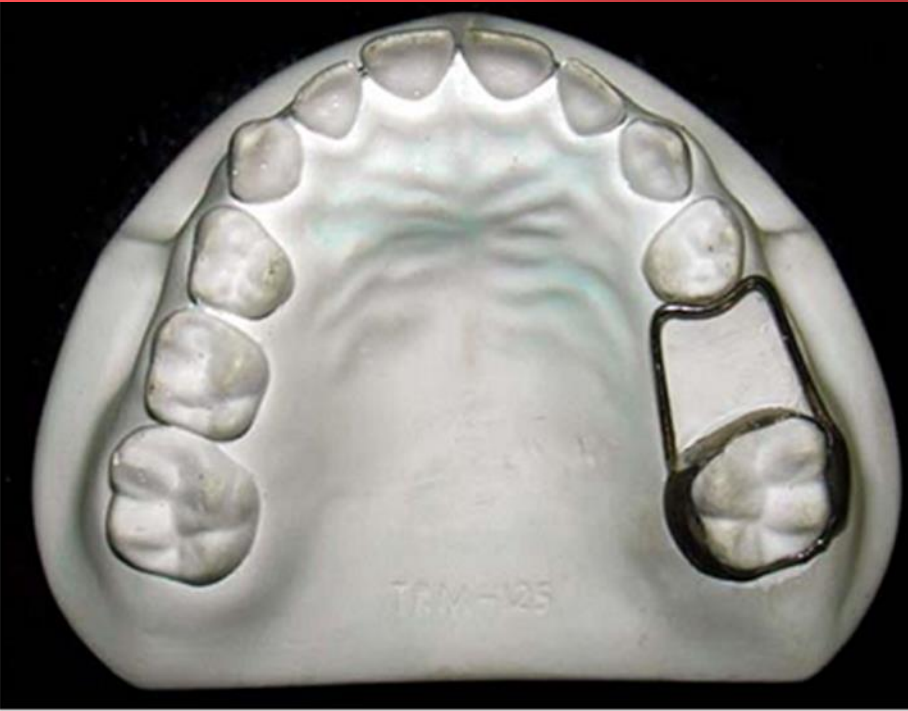MOST COMMON CAUSES OF OCCLUSAL ABNORMALITIES

- 1- Retained (ankylosed) deciduous teeth:** may cause malalignment of the permanent successor and lack of development of the alveolar process.
- 2- Poor restoration:** loss of contacts due to caries or *inadequately* contoured fillings may lead to loss of space.

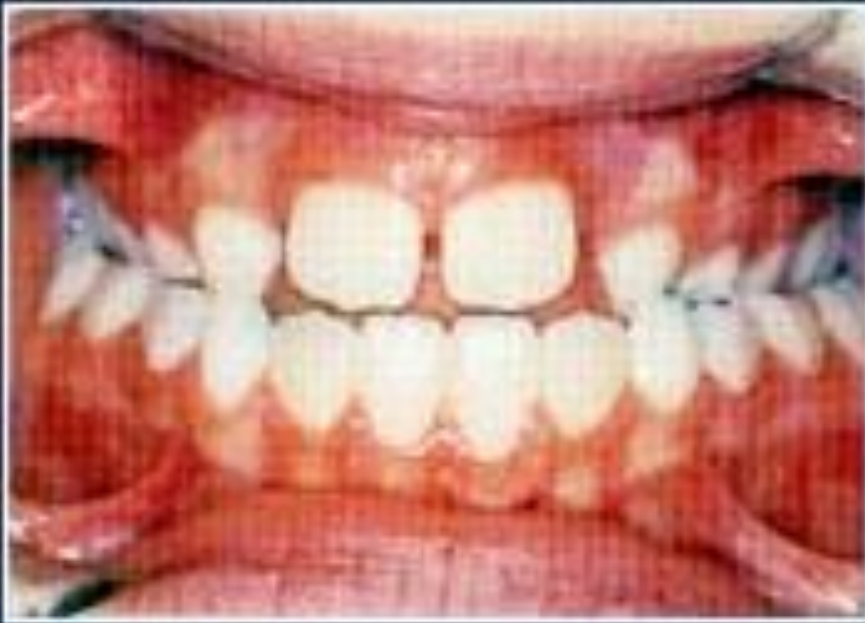



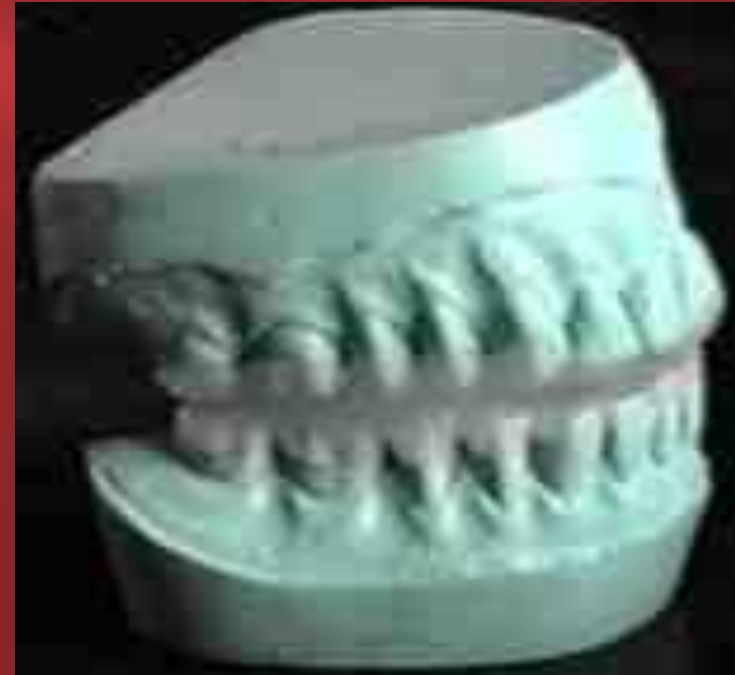3- Early loss of deciduous teeth; may lead to space loss. Careful attention and space maintainer restoration when it is indicated.

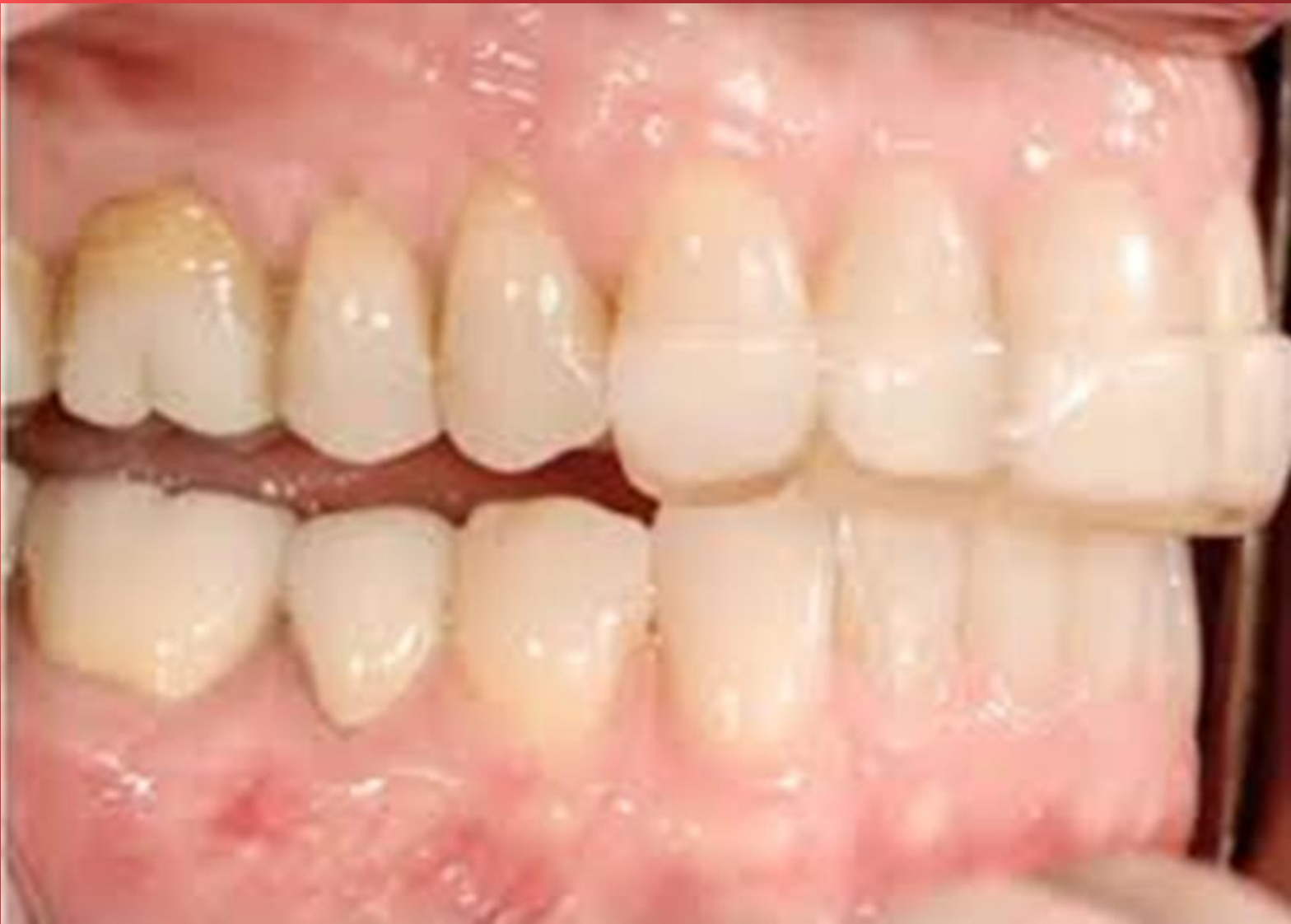

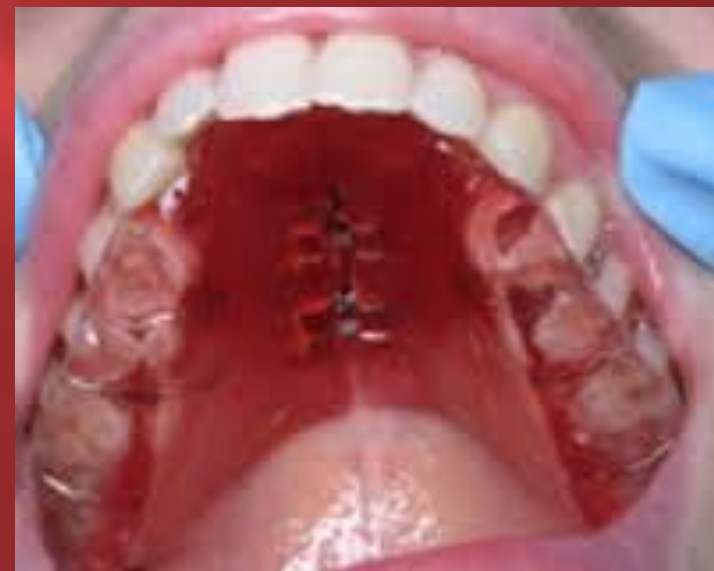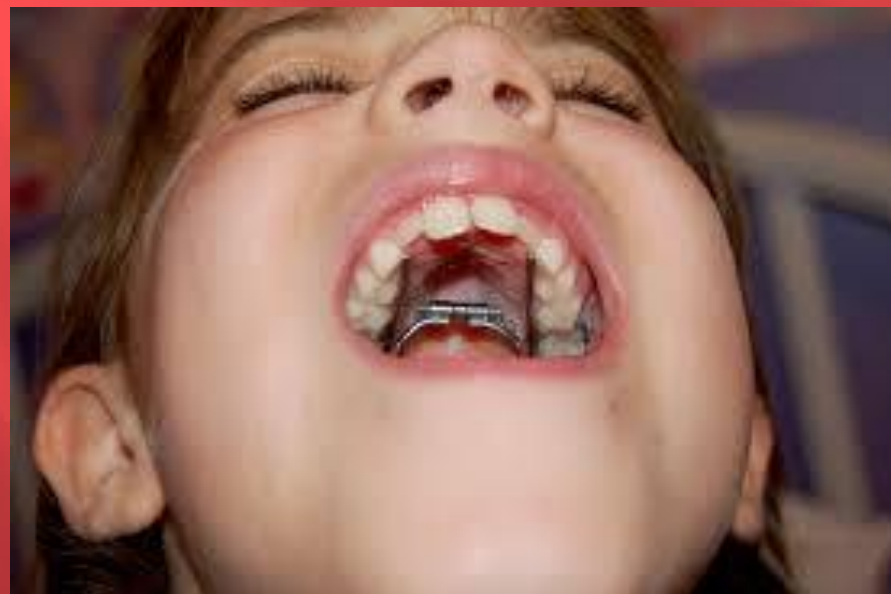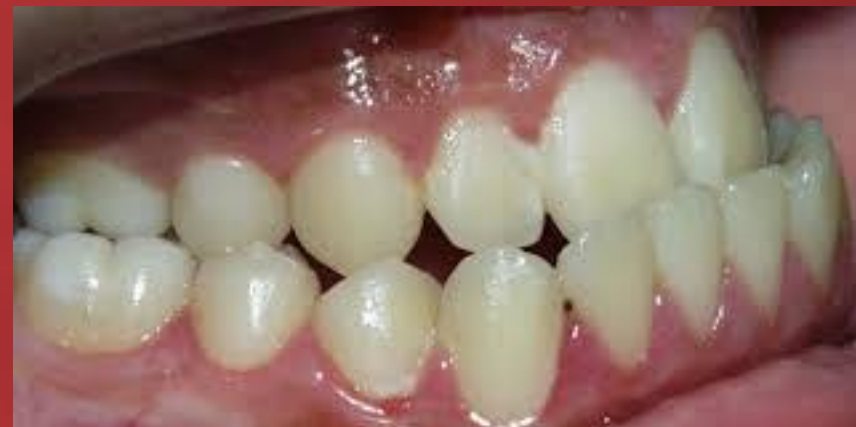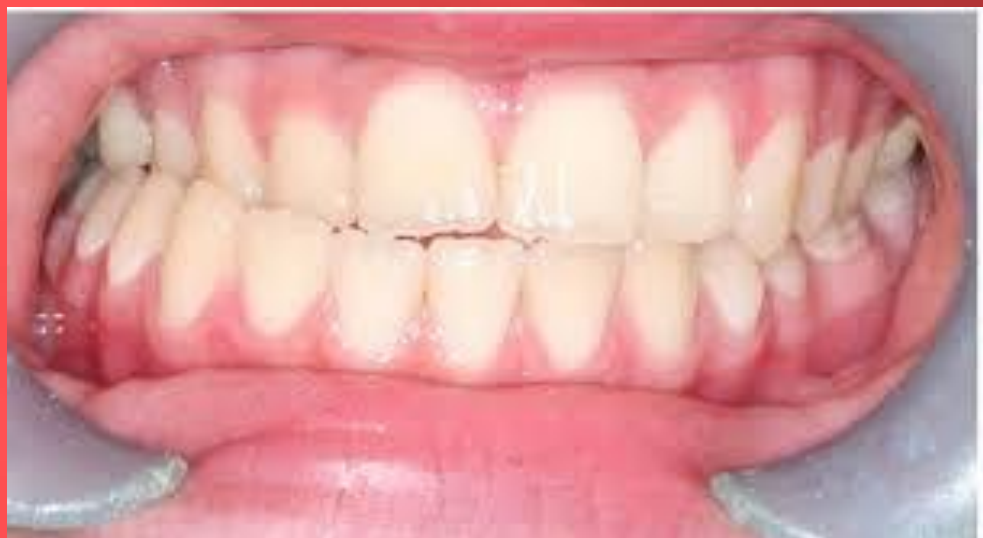4- *Crossbites* in wholly deciduous arches do not require orthodontic interference, usually not corrected by this early treatment.

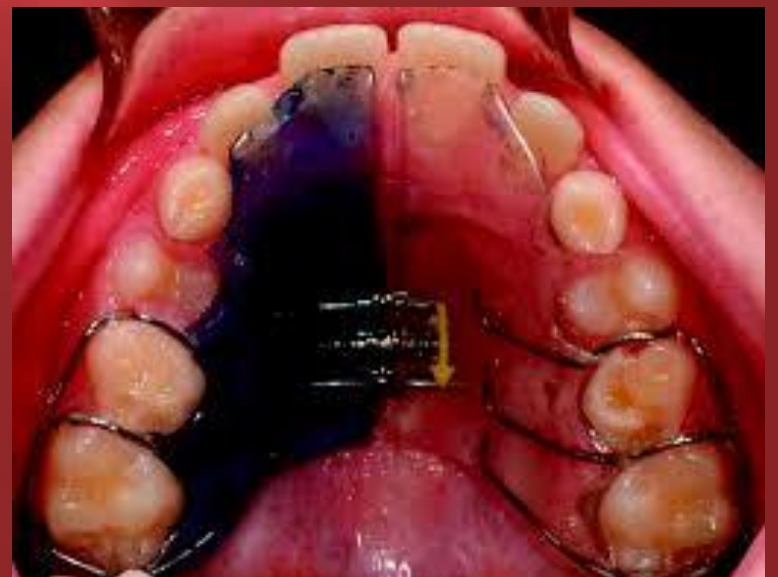
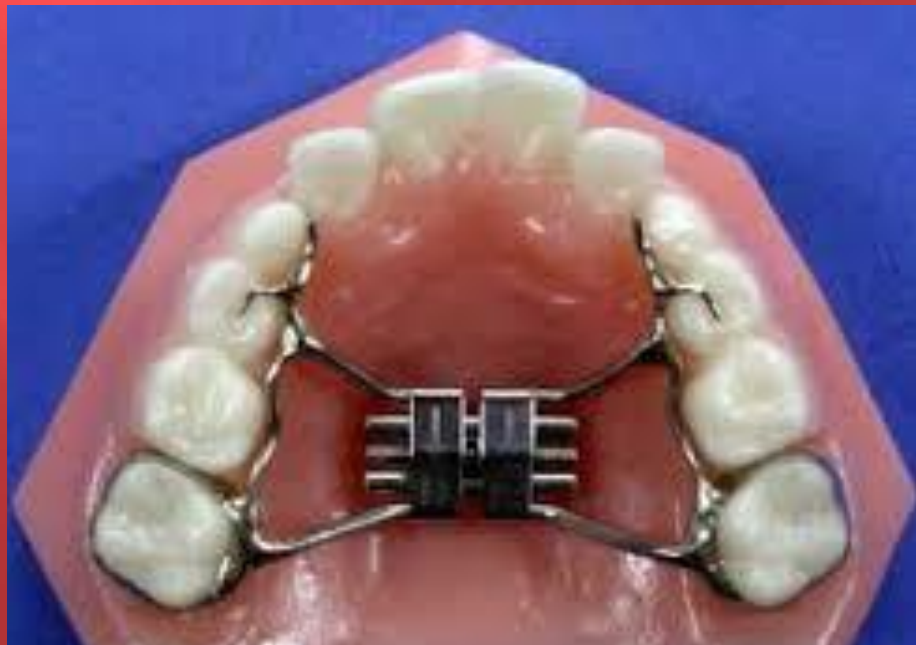
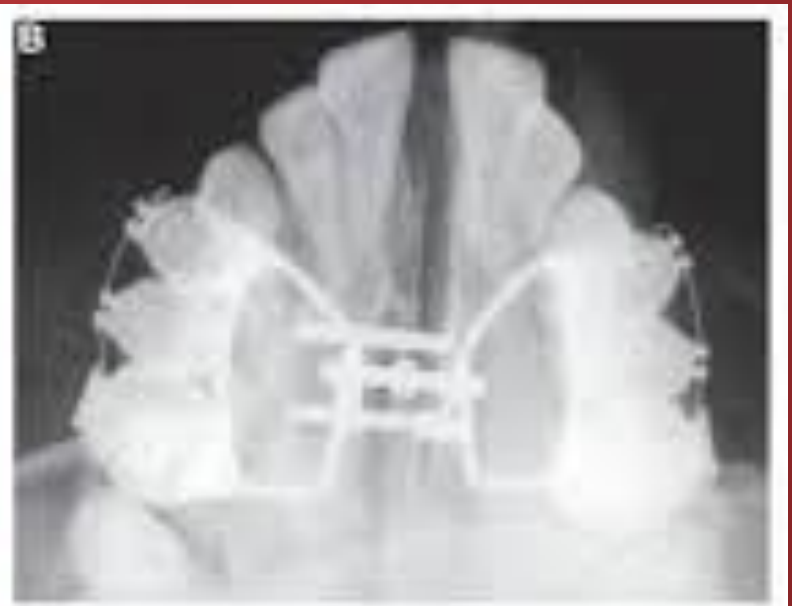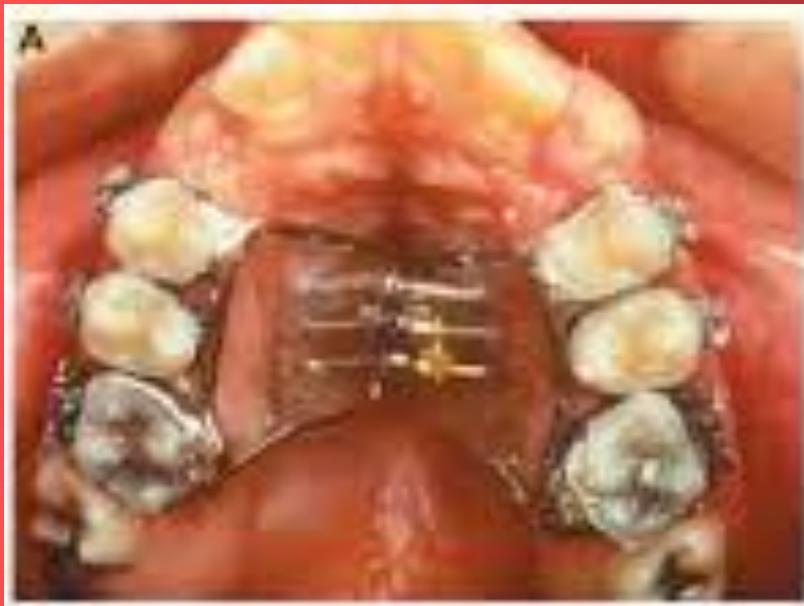Crossbite

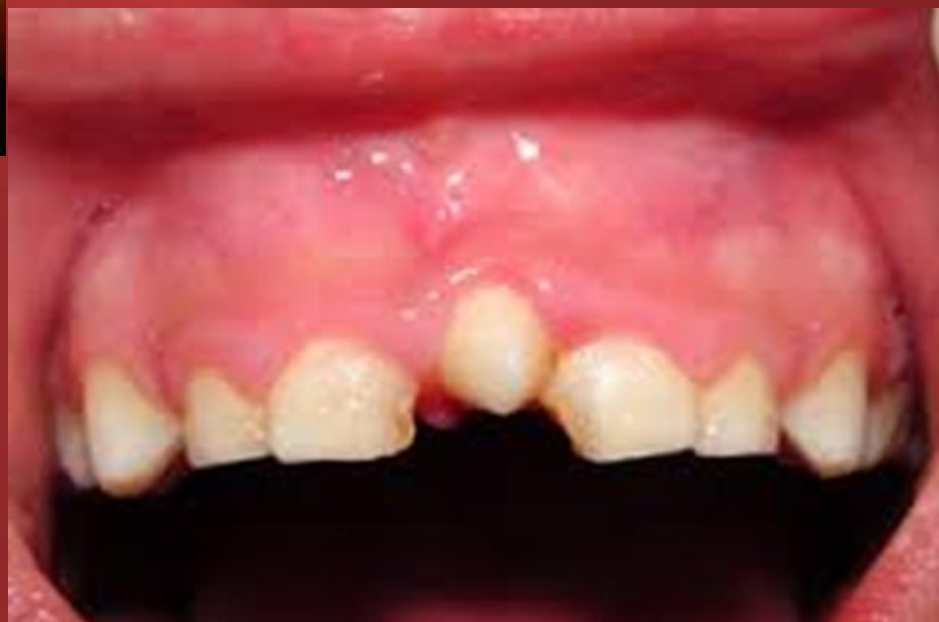
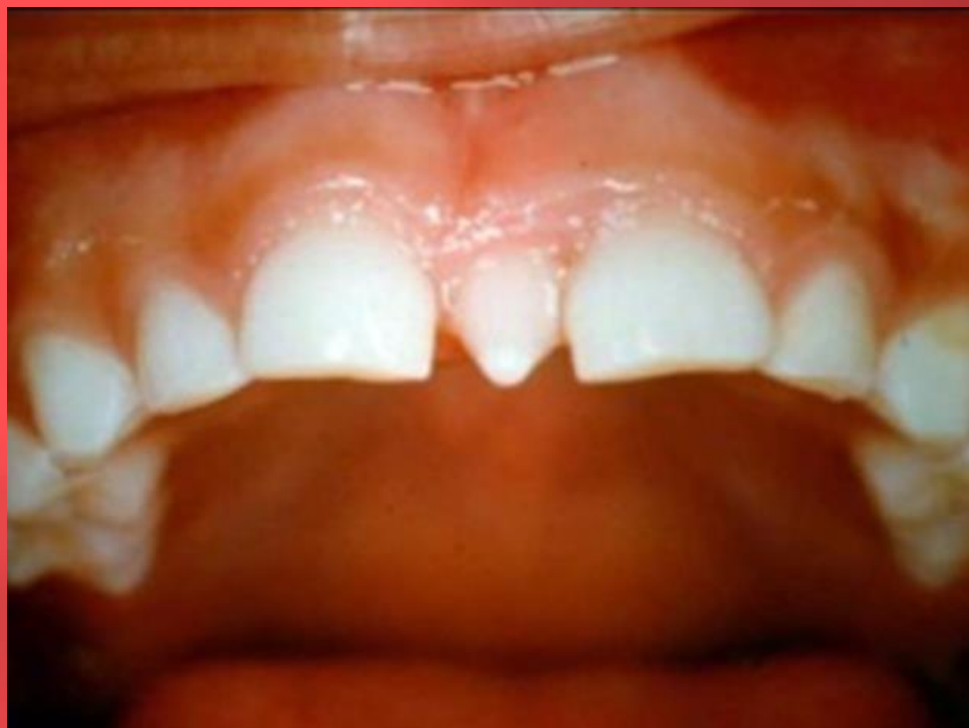


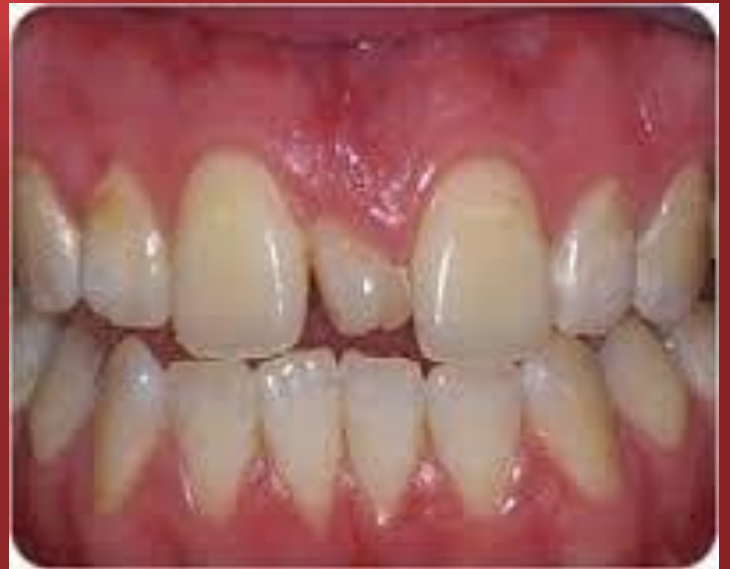
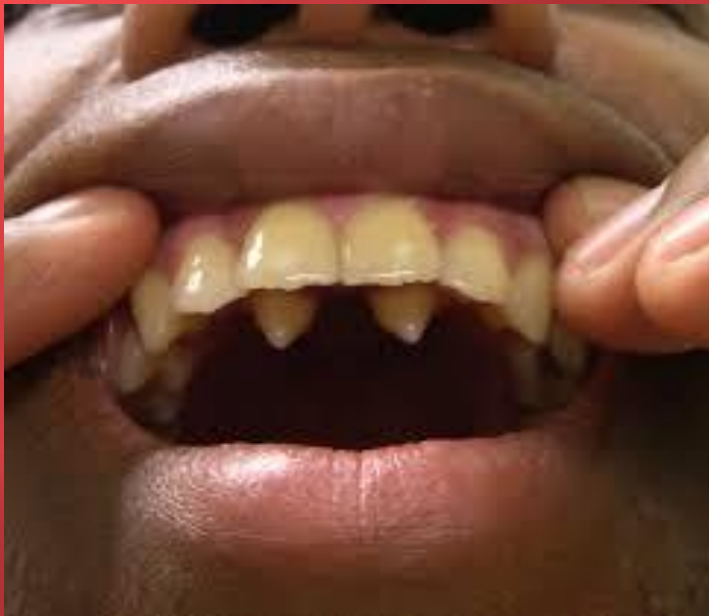
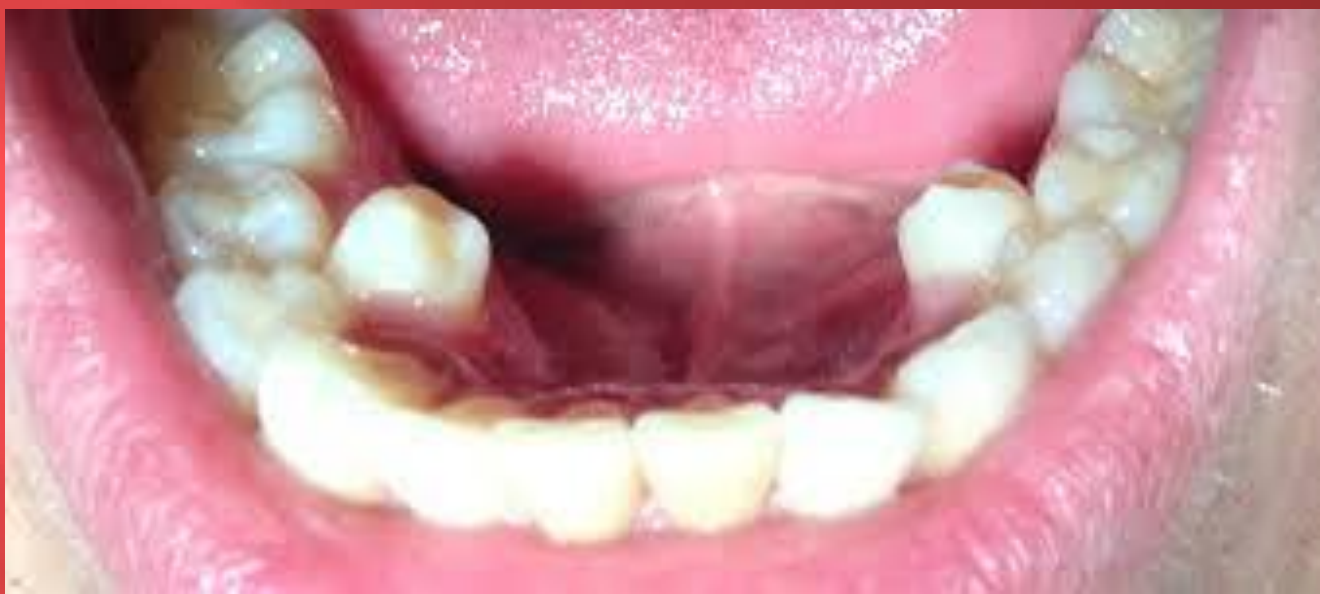

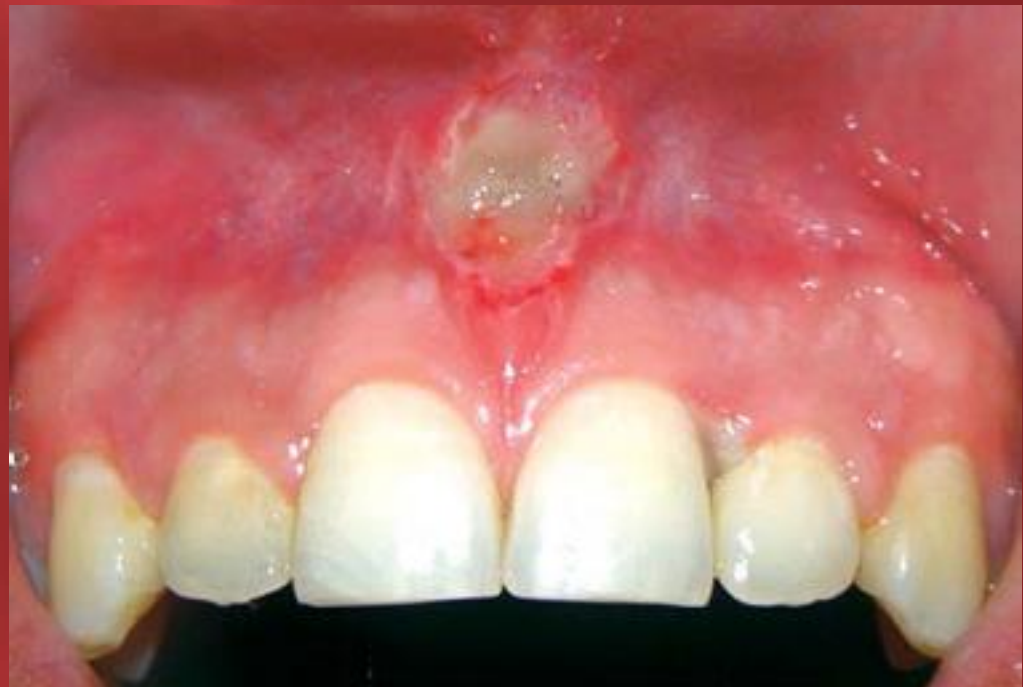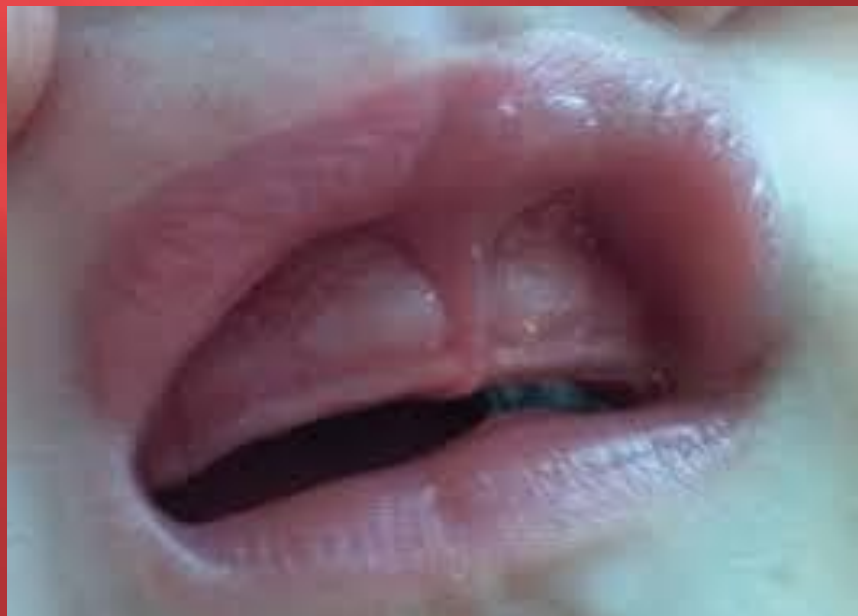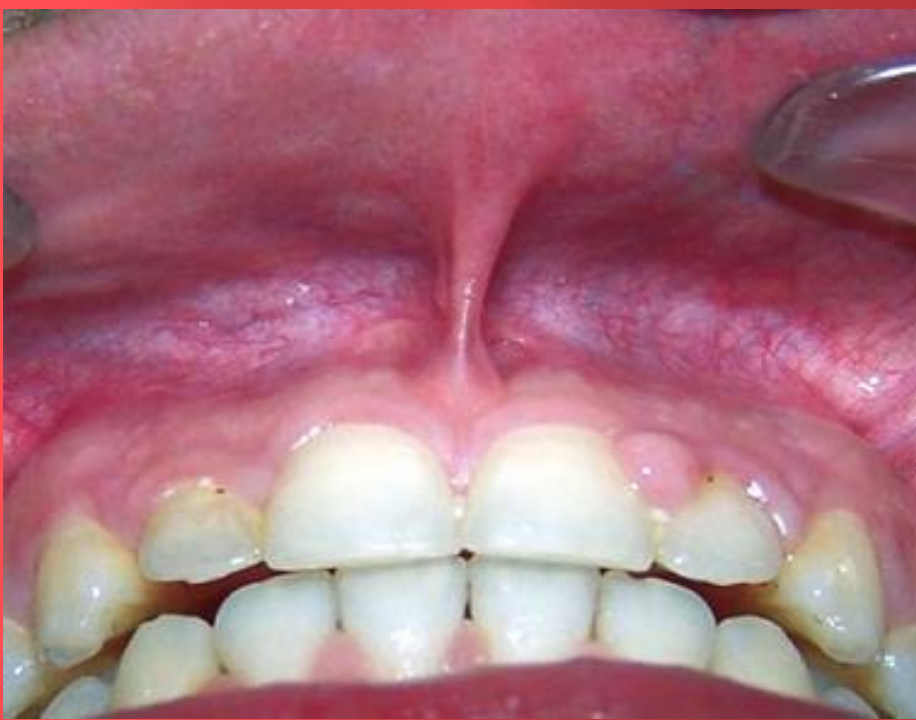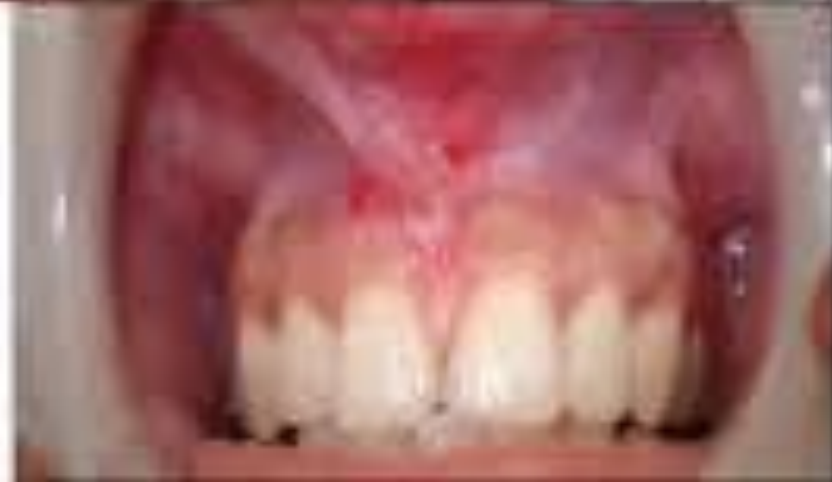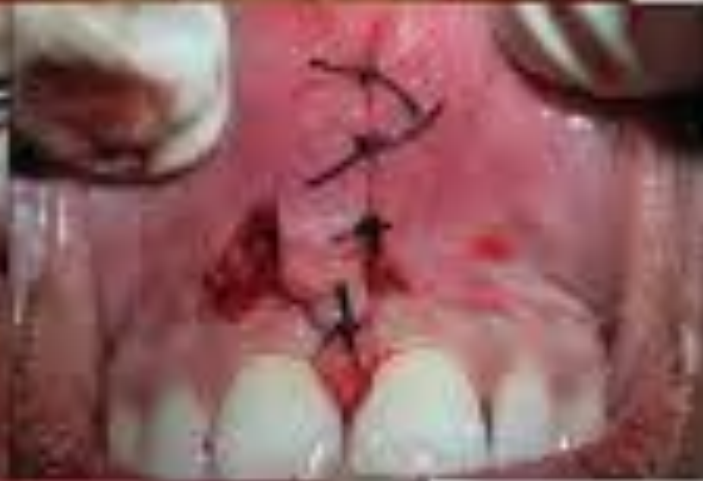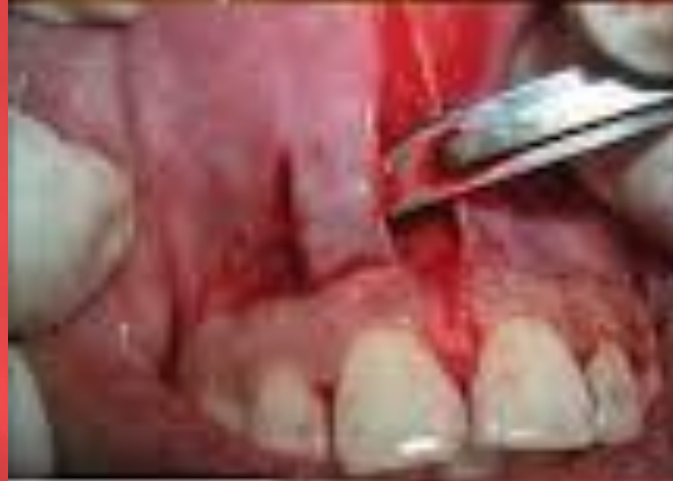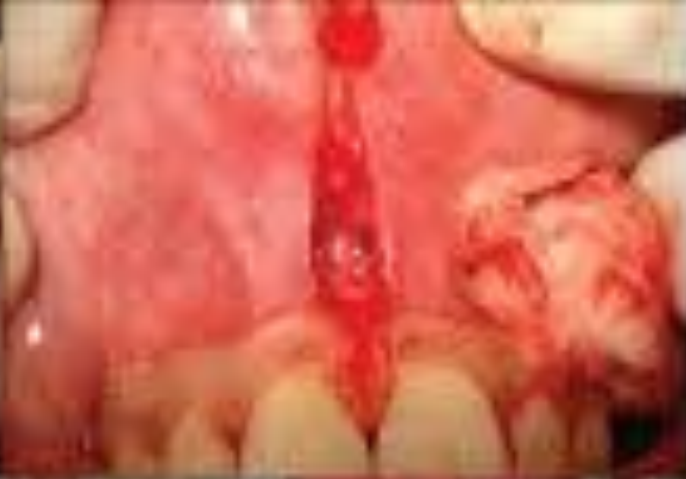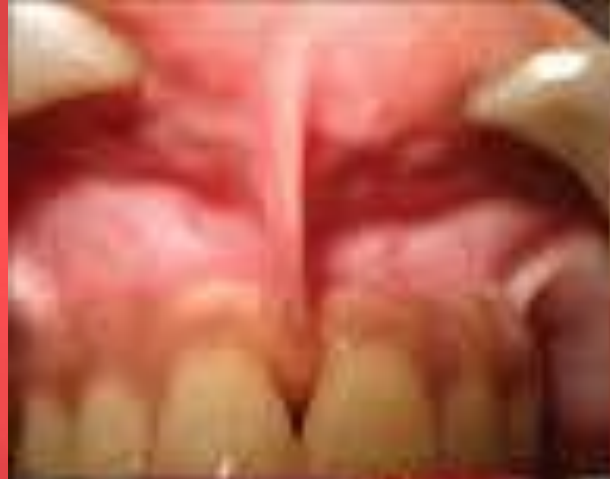5- Unerupted or erupted supernumerary teeth

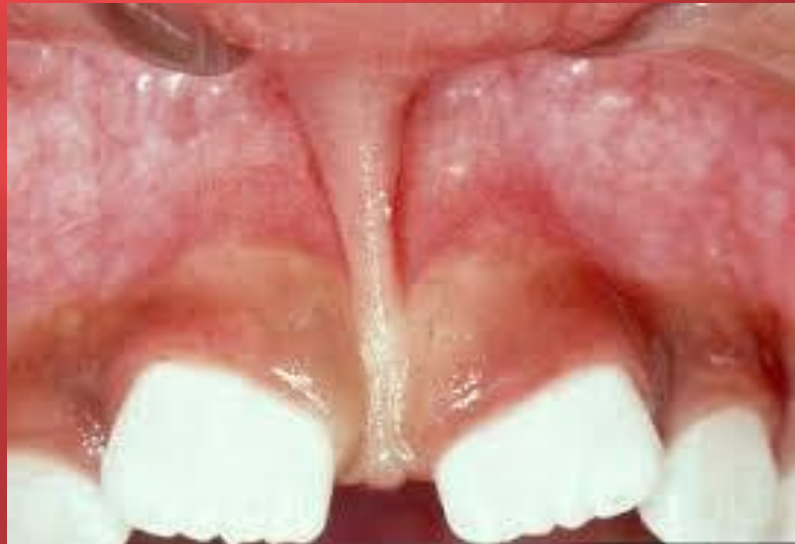
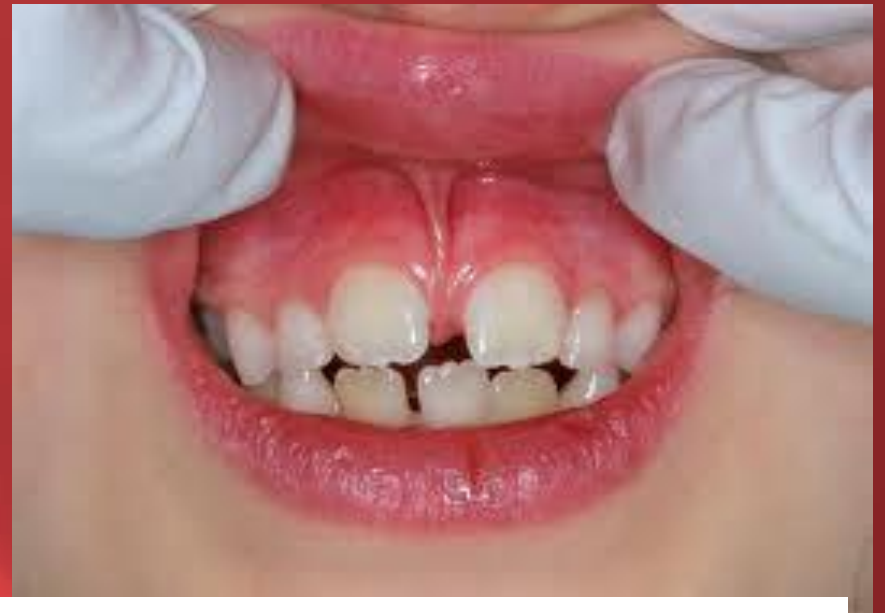
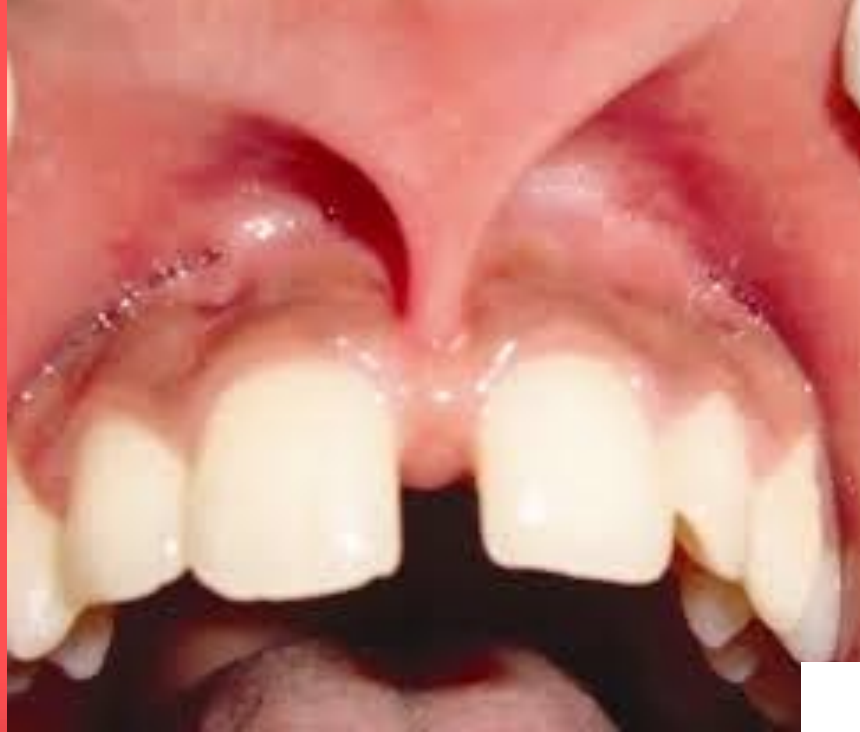

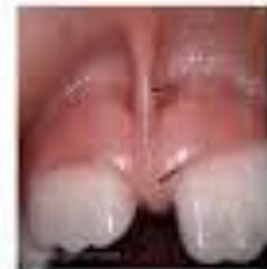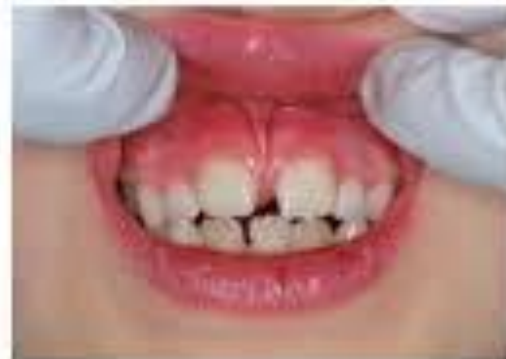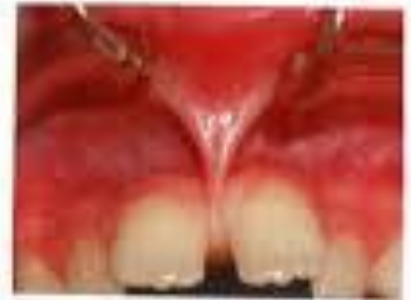6- ABNORMAL FRENAL ATTACHMENTS

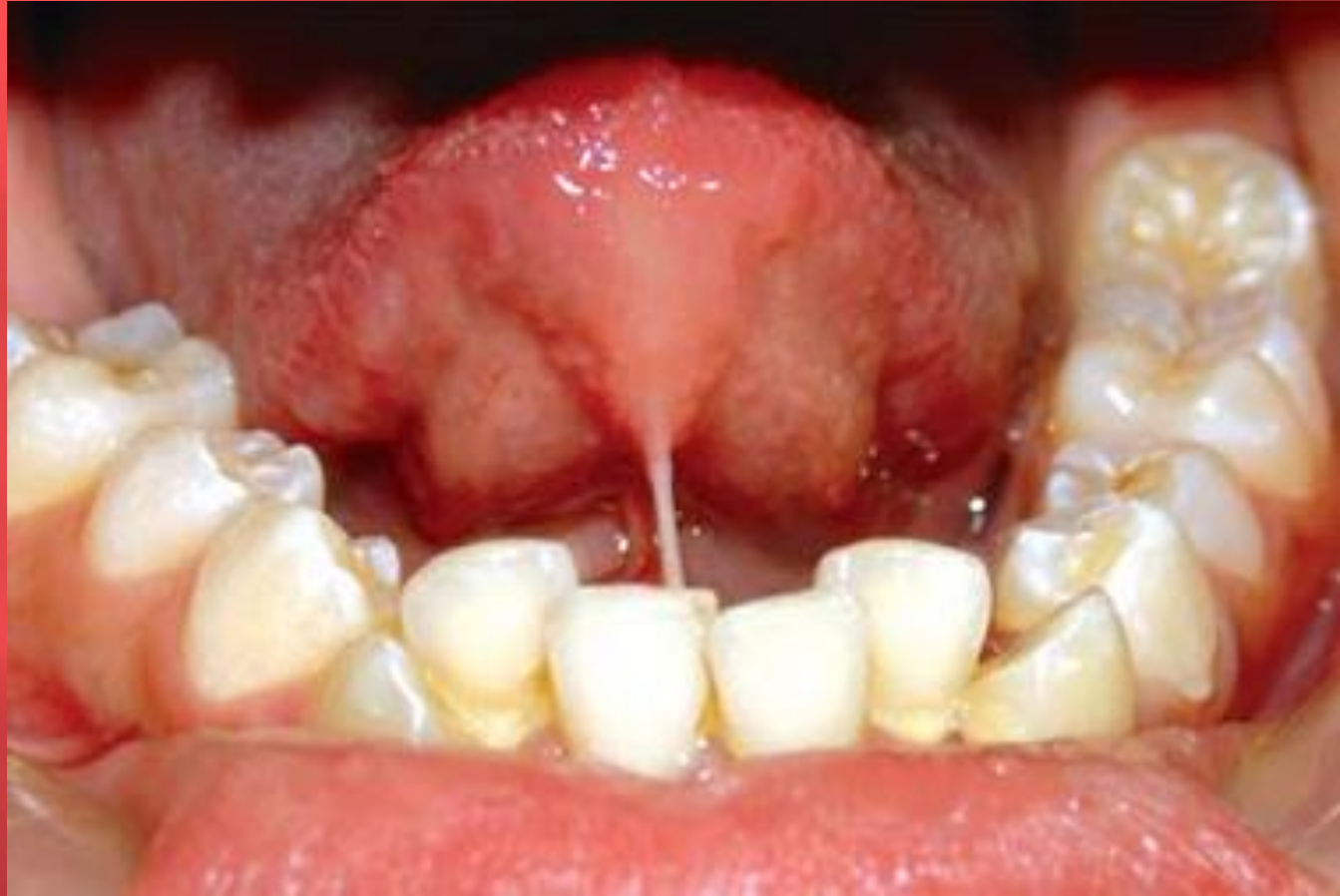





Abnormal Labial Frenum





7- Ectopic eruption of the first permanent molars: The mesially positioned molar may cause premature resorption and exfoliation of the second primary molar a problem.

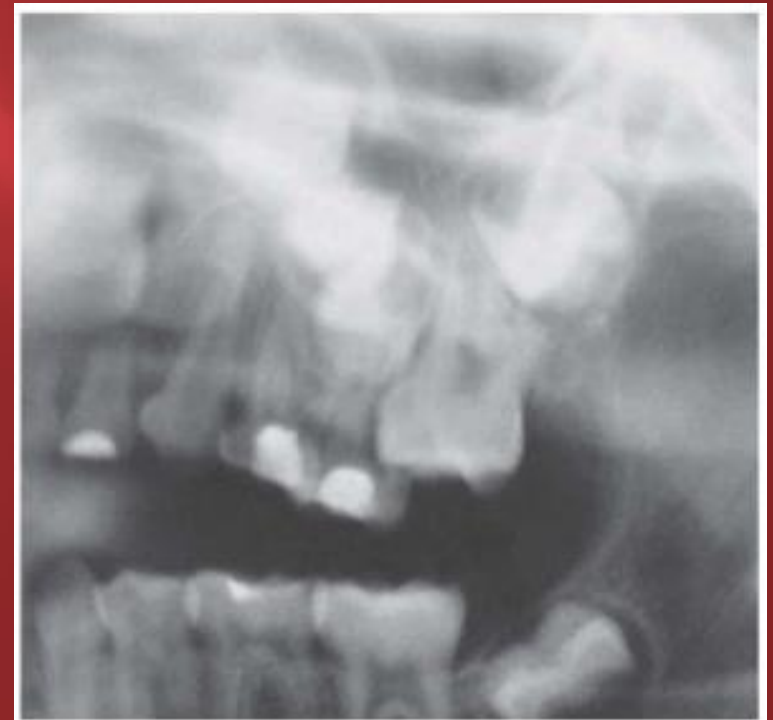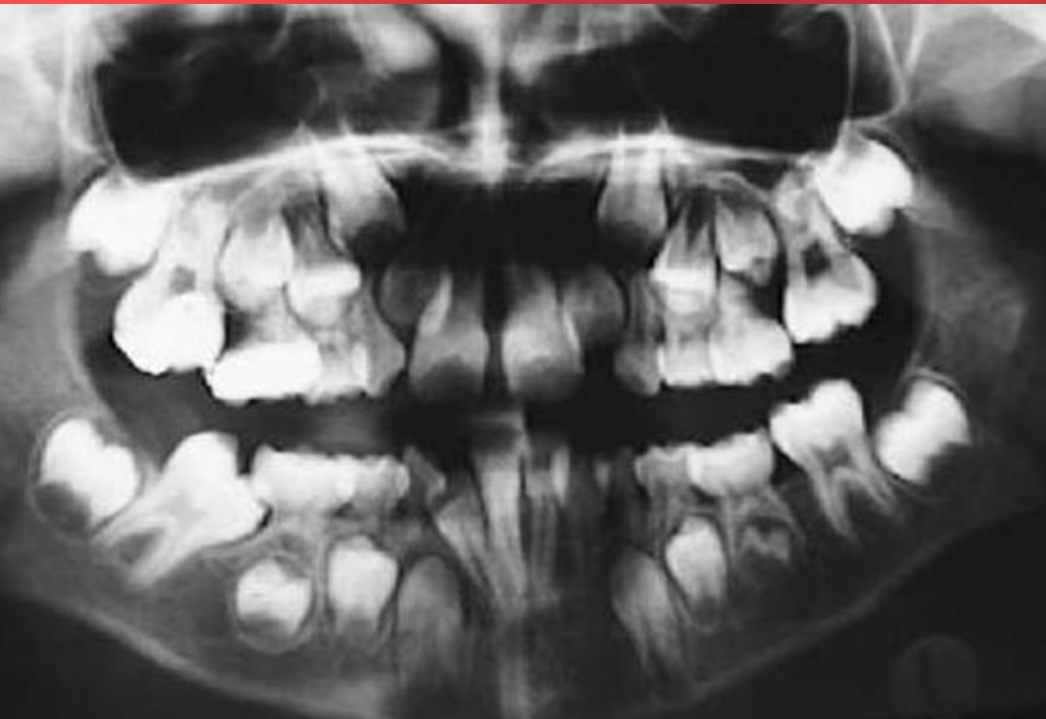


FIGURE 5- Irreversible ectopic eruption of the permanent maxillary left first molar

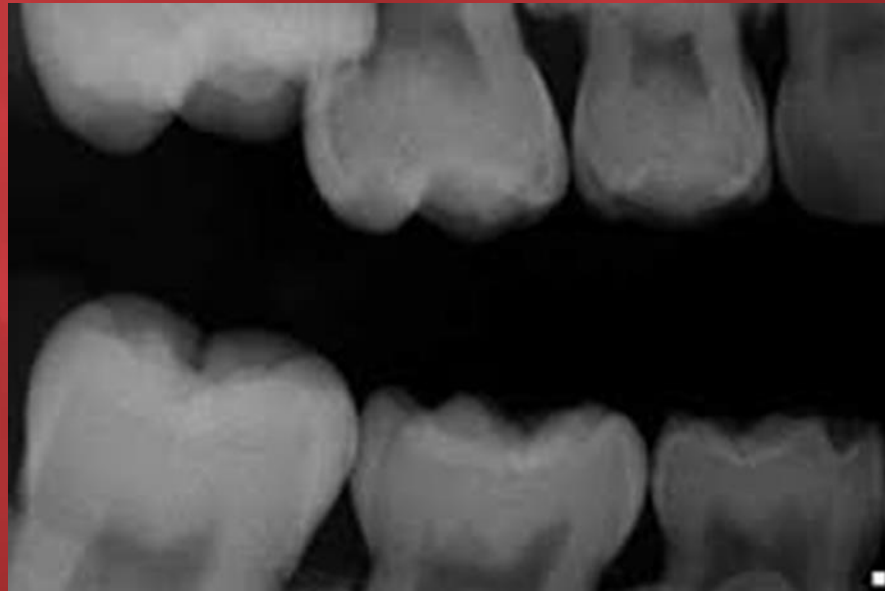Age: 5-6 year

Sex: boys > girls.

Site: Maxillary > mandibular.

approximately 3% of the population.

Diagnosis: Full mouth radiographs at 5 or 6 years of age are essential for early diagnosis.



Complication:

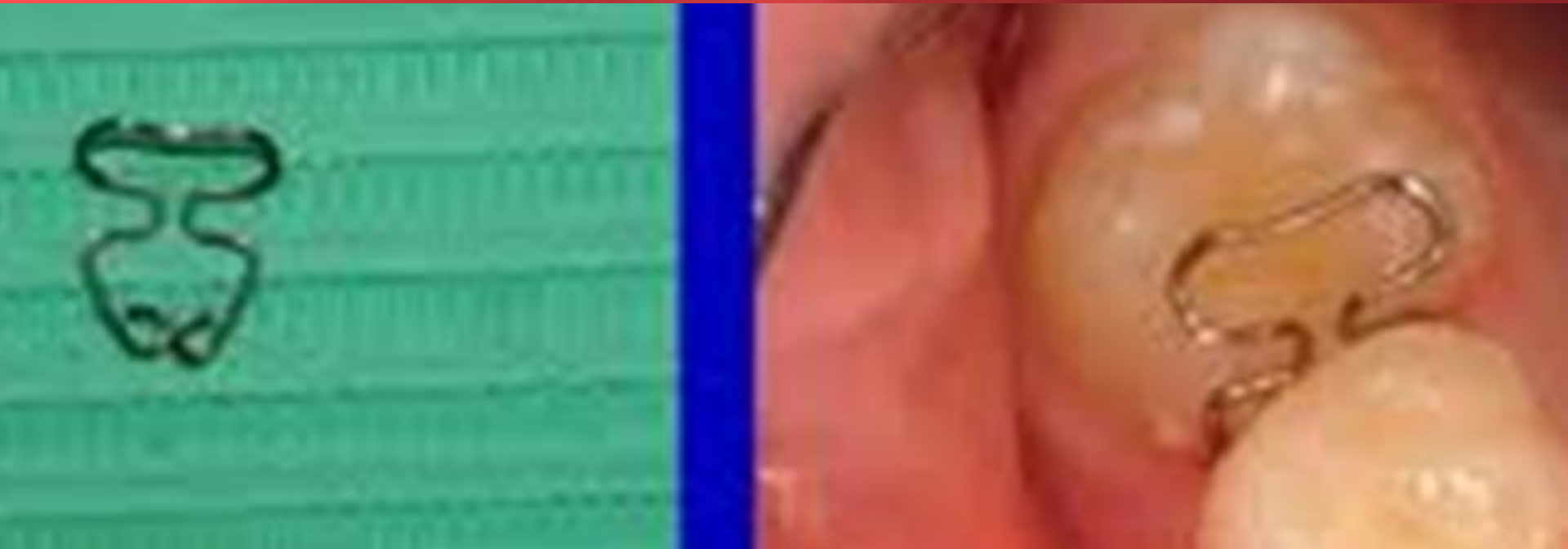Neuralgic pain resulting probably from the resorption of the distal portion of the second primary molar, break in the epithelial attachment that allows the ingress of oral fluids and resultant pulpal inflammation. If this occurs, the primary tooth must be removed.

Treatment

It is self treated in two thirds of the cases reported,

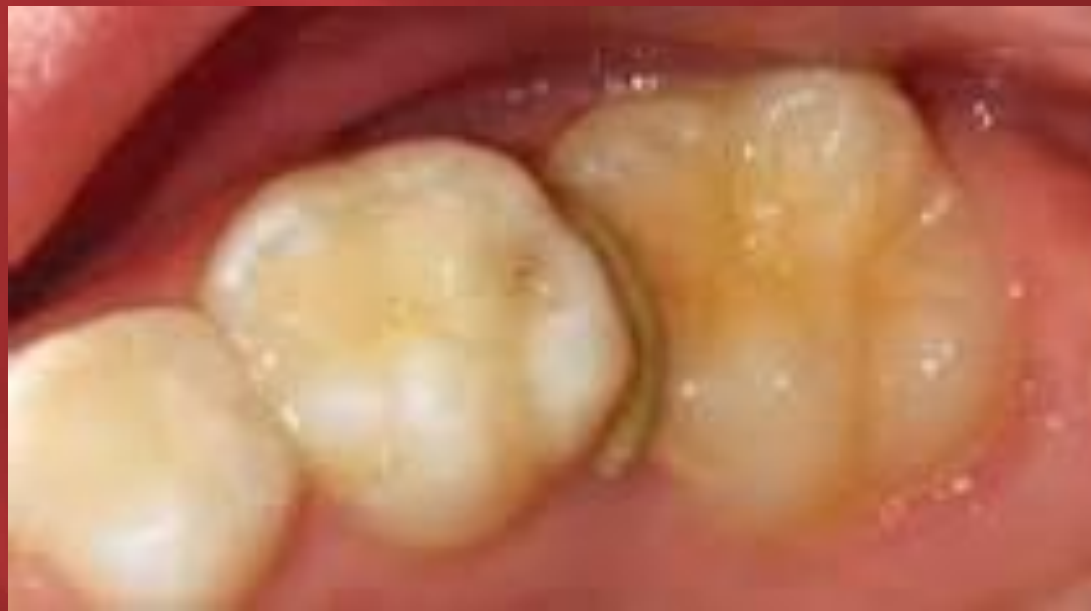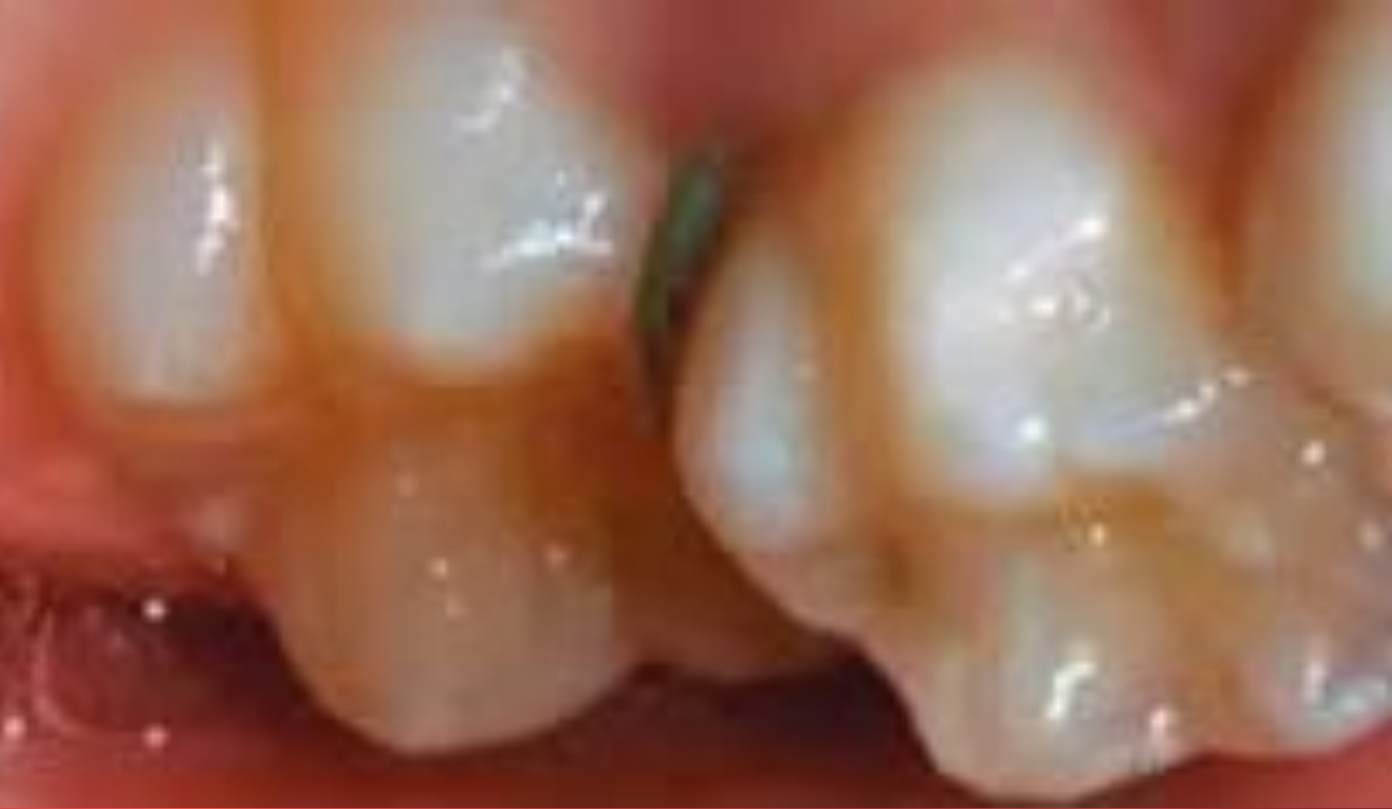one third require correction.

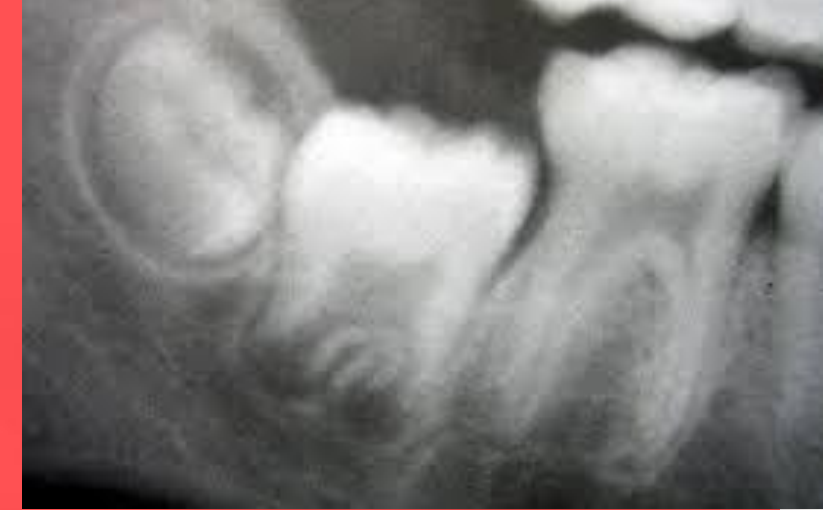1-A prefabricated wire separator provides the simplest form of treatment.



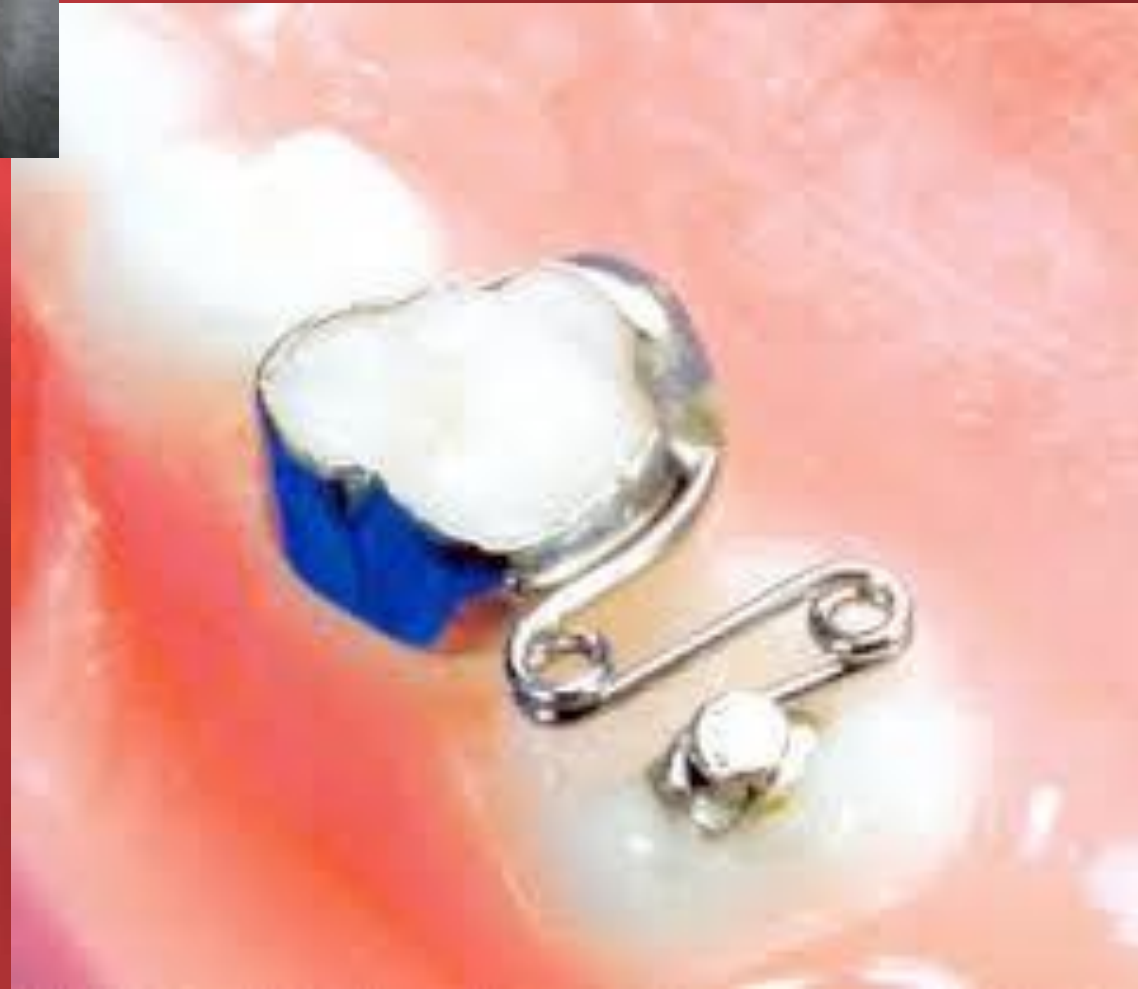2- use of a brass separating wire (0.5 or 0.6mm) tightened around the contact area, and retightened every 2 to 3 days.

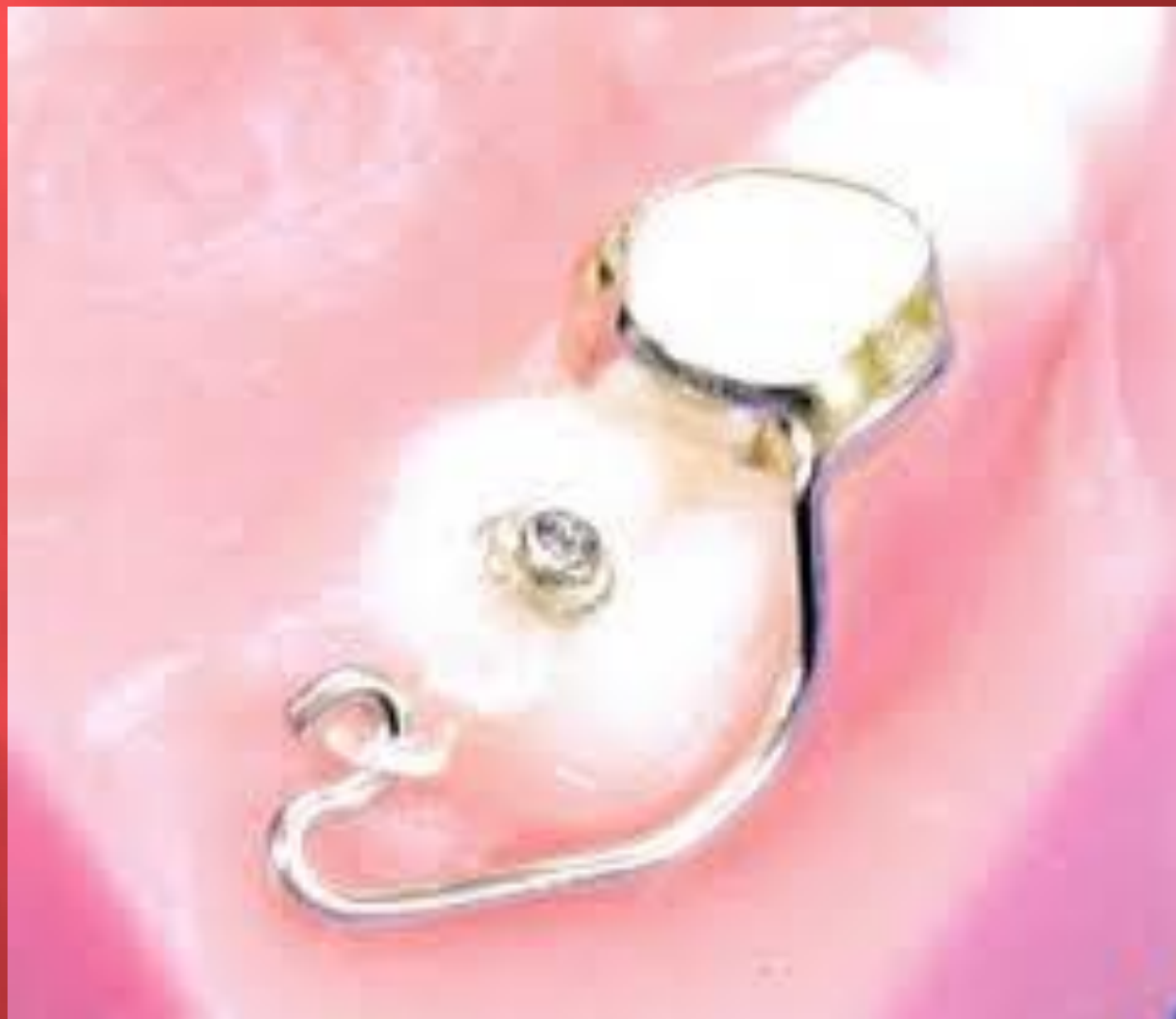The wire will cause disto-occlusal movement of the first permanent molar if the contact opens during treatment a thicker wire should be used.





3-Orthodontic button bracket and band

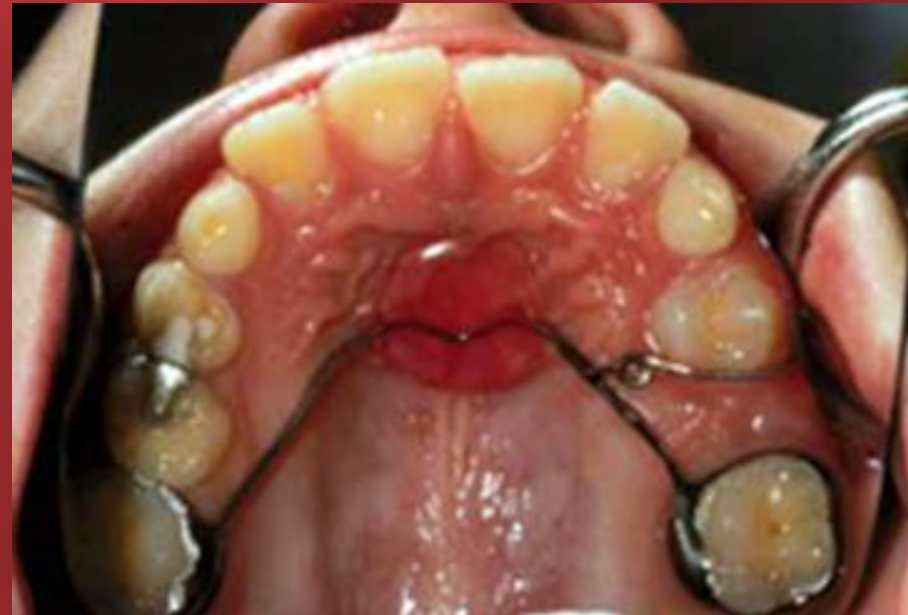



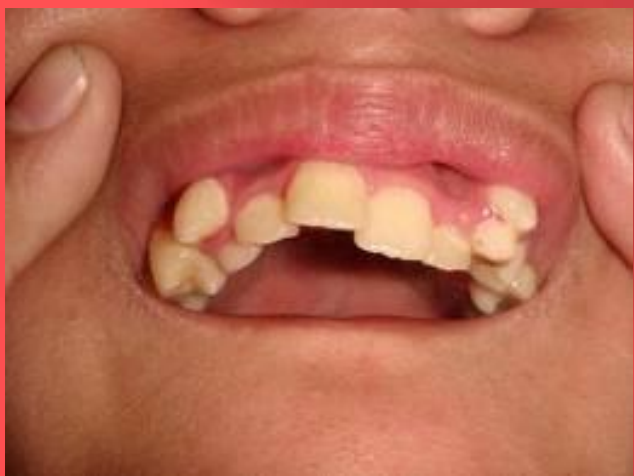4- Gingivally overextended band on the second primary molar to provide a smooth guiding surface for the permanent molars.



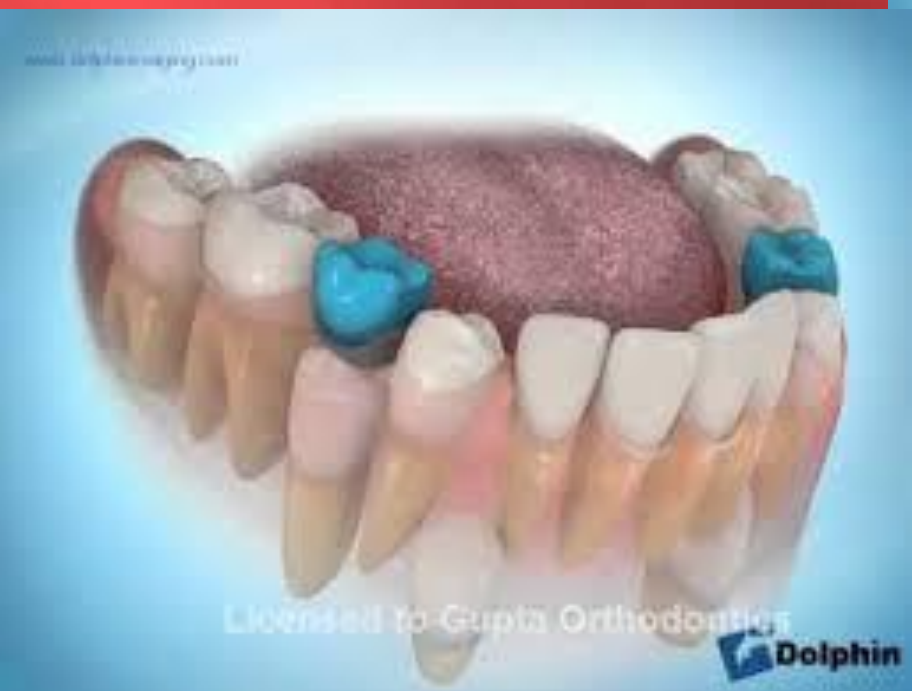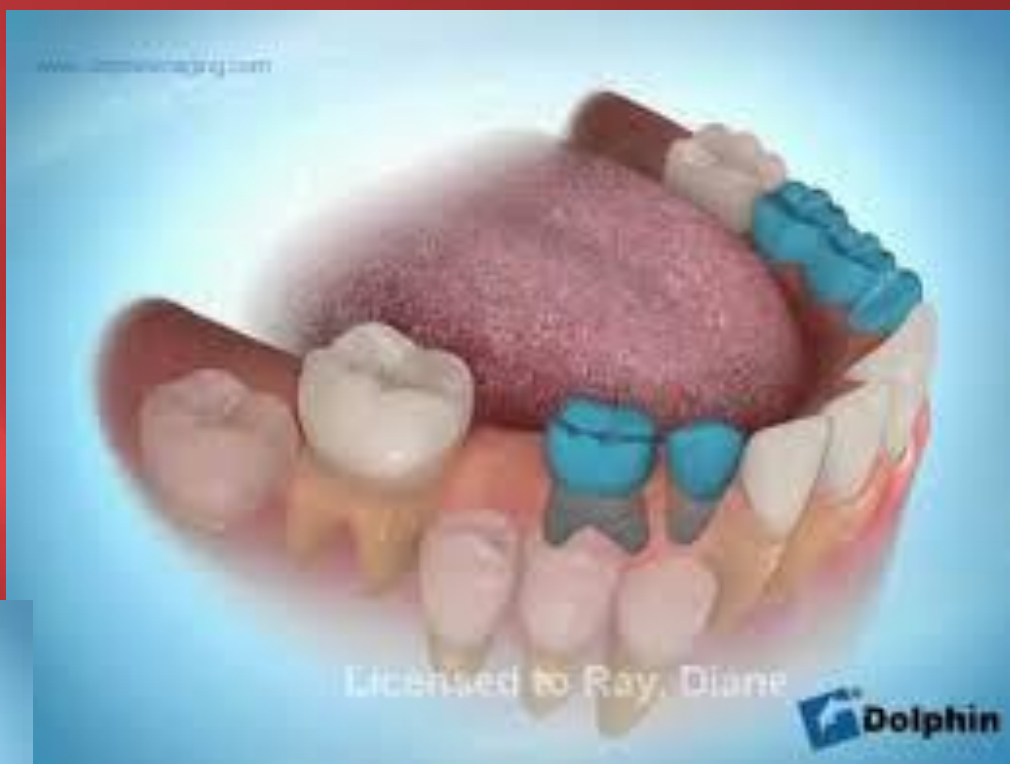5-Extraction of the second primary molar and construction of an active appliance (space regainer)
to distalise the permanent molar into its proper position prior to the placing of a passive space maintainer is the treatment of the choice.

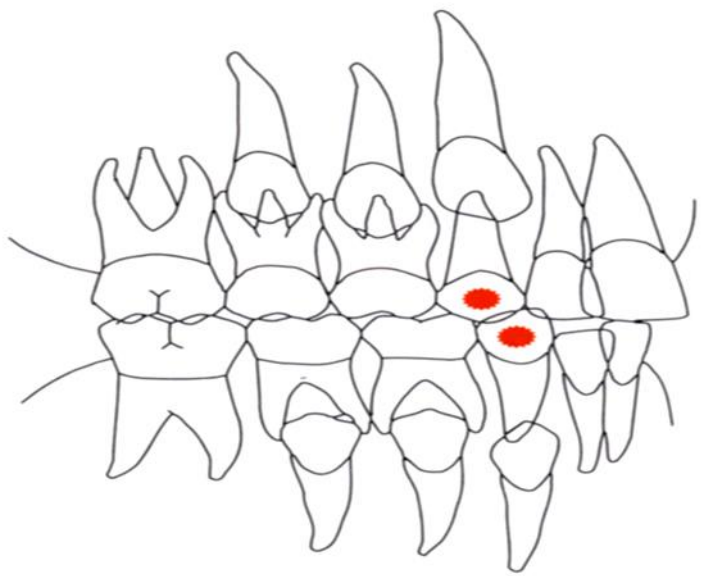


8- Crowded anterior region with class I malocclusion:

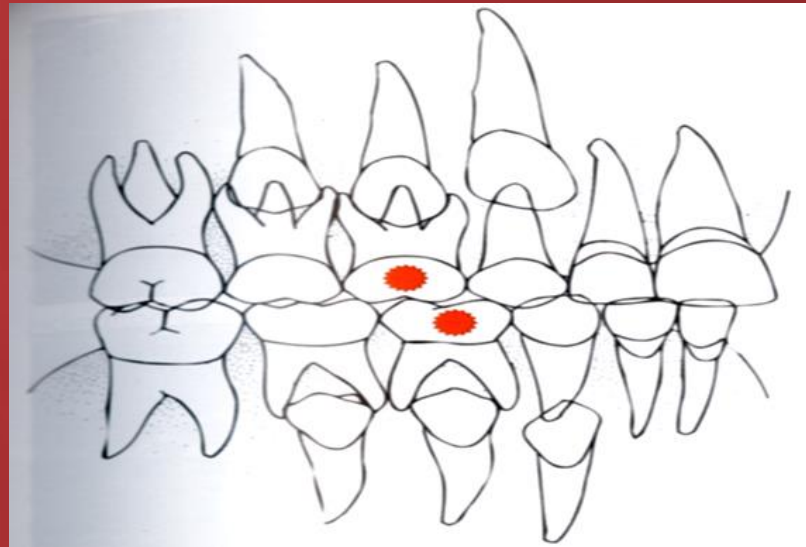


Ttt: serail extraction

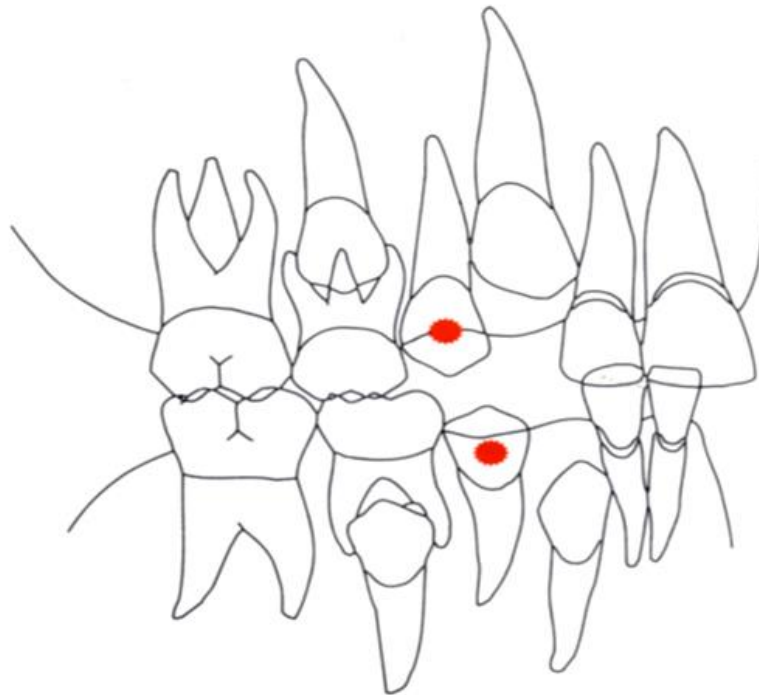




A



A



C